

Necrotizing ulcerative periodontitis: a diagnostic indicator of immunosuppression

Medhini Madi¹, Mathangi Kumar¹, Anupam Singh², Ravindranath Vineetha¹, Komal Smriti¹, Srikanth Gadicherla²

¹Department of Oral Medicine and Radiology, Manipal College of Dental Sciences, Manipal, Manipal Academy of Higher Education, Manipal 576104, Karnataka, India

²Department of Oral and Maxillofacial Surgery, Manipal College of Dental Sciences, Manipal, Manipal Academy of Higher Education, Manipal 576104, Karnataka, India

Abstract

This case report describes and discuss the significance of necrotizing ulcerative periodontitis. A wide range of oral lesions has been documented in individuals infected with the potential life-threatening human immunodeficiency virus (HIV). HIV-infected patients are at an increased risk of a unique form of periodontal disease called 'necrotizing ulcerative periodontitis'. These lesions are the most severe form of periodontitis identified but of rare occurrence among HIV patients, with a prevalence of less than 5%. Disease progress is managed by thorough local debridement under antibiotic coverage. Here, we report a case of a 44-year-old female who reported with an extensive area of ulcerations, and necrosis of marginal gingiva, interdental papilla, and attached gingiva. Blood investigations revealed an absolute CD4+ cells count of 75 cells/mm³ and HIV-positive status. Necrotizing ulcerative periodontitis is as an indicator of underlying systemic immunosuppression. Further, the occurrence of ulcerative periodontitis led to the diagnosis of HIV in the present case.

HIV AIDS Rev 2022; 21, 2: 175-178
DOI: <https://doi.org/10.5114/hivar.2022.115542>

Key words: AIDS virus, human immunodeficiency virus, immunosuppression diagnoses, highly active antiretroviral therapy.

Introduction

A wide range of oral lesions has been documented in individuals infected with the potential life-threatening human immunodeficiency virus (HIV). Unremitting immune deterioration throughout the advancement of the disease causes a multitude of oral and systemic manifestations. HIV-infected patients are at an increased risk of a unique form of periodontal disease called 'necrotizing ulcerative periodontitis'.

In the year 1999, during international workshop organized by the American Academy of Periodontology, necrotizing ulcerative periodontitis (NUP) was classified as one among the earliest oral lesions associated with HIV infec-

tion. These lesions are the most severe form of periodontitis identified but of rare occurrence among HIV patients, with a prevalence of less than 5% [1]. This distinctive periodontal disease was initially stated as AIDS-virus-associated periodontitis (AVAP) or HIV-associated periodontitis (HIV-P) by Winkler and Murray [2]. 2017 workshop on reclassification of periodontitis suggested necrotizing periodontitis as a distinctive entity [3]. NUP is a well-recognized sequela of necrotizing ulcerative gingivitis (NUG). This fusospirochetal gingivitis, termed as 'trench mouth', was classically noted amongst military workforces during World War I, probably owing to numerous risk factors, such as reduced

Address for correspondence: Komal Smriti, Department of Oral Medicine and Radiology, Manipal College of Dental Sciences, Manipal, Manipal Academy of Higher Education, Manipal 576104, Karnataka, India, e-mail: komalms1@gmail.com

Article history:
Received: 19.05.2020
Received in revised form: 01.01.2021
Accepted: 24.10.2021
Available online: 13.04.2022



oral hygiene, extreme mental, emotional stress, and under-nourishment [4]. Very few cases of NUP have been documented in the general public, but an increased incidence was noted in immunocompromised patients, especially HIV-infected individuals. NUG could be the earliest and foremost sign of HIV infection [5]. Here, we report a case of NUP in a middle-aged woman, with no prior history of retroviral illness.

Case description

A 44-year-old female patient reported with a complaint of pain in the upper and lower gums since seven days. History revealed that she noticed redness of the gums in the lower front region for seven days. Two days later, she noticed widespread redness of gums associated with severe pain. The patient experienced deep-seated, continuous pain that was radiating to forehead and ear. She had difficulty in chewing, foul smell, and altered taste in the mouth. She also felt dryness and stickiness in the mouth. She was unable to brush her teeth properly due to profuse bleeding from the gums while brushing, and noticed a gradual change in the color of the gums to yellowish with pus discharge from various areas. The patient consulted a local dentist who prescribed analgesics and anti-

biotics, and referred her to our hospital for further management. She reported that the pain has only mildly subsided.

Medical history of the patient revealed that she did not have any other comorbid illness. She said that her husband had expired due to some illness two years back. The patient was moderately built and nourished, with vital signs under normal limits. The right and left submandibular lymph nodes were palpable, measuring approximately 0.5 cm × 0.5 cm in dimension, firm in consistency, mobile, and non-tender. On intra-oral examination, there was generalized gingival recession with abundant calculus and halitosis with bleeding from gums on probing. The gingiva showed necrosis and pale yellow appearance. Area of ulcerations and necrosis of the marginal gingiva were noted, with inter-dental papilla and attached the gingiva, surrounded by erythematous halo covered with a whitish-yellow soft layer (pseudo-membrane). There was alveolar bone exposure in the region of 15, 16, 31, 41, and 42. Necrosis of the gingiva was evident in tooth-bearing areas (Figure 1). On palpation, there was severe gingival tenderness. Also, deep interdental osseous craters, presence of pus discharge on manipulation from left posterior gingiva with grade 1 mobility w.r.t. 31, 32, 41, and 42 were noted.

Panoramic radiograph revealed generalized moderate interdental bone loss, suggesting moderate chronic periodontitis. There was no radiographic evidence of bone necrosis (Figure 2). A provisional diagnosis of necrotizing ulcerative periodontitis secondary to immunocompromised status was considered, and the patient was advised for blood investigations.

Blood investigations revealed hemoglobin levels of 10.2 g/dl and lymphocyte count of 7.4%. Absolute CD4+ cells count was 75 cells/mm³. Considering her CD4+ levels, further investigation to confirm HIV infection, including ELISA test and HIV differentiation assay, was advised. Results of these tests were positive, which confirmed retroviral status of the patient. She was counselled regarding the immunocompromised state, and was referred to department of medicine for further evaluation and management. The patient was promptly started with highly active antiretroviral therapy (HAART).

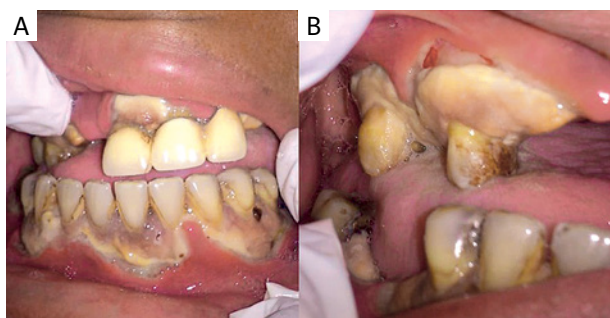


Figure 1. Severely necrosed, pale yellow appearing gingiva in the upper and the lower arches. Area of ulcerations, and necrosis of marginal gingiva, inter-dental papilla, and attached gingiva

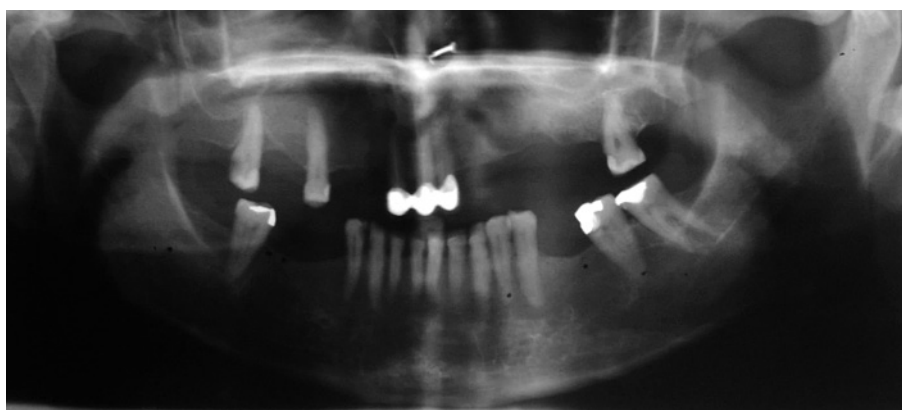


Figure 2. Panoramic radiograph showing generalized moderate interdental bone loss

For the management of her periodontal condition, she was referred to department of periodontology. Hydrogen peroxide swabbing was done, followed by debridement and irrigation of ulcerated area with 0.2% chlorhexidine. Sub-gingival scaling was planned one week later, and systemic antibiotics amoxicillin was prescribed, with clavulanate potassium twice daily and metronidazole thrice daily for one week. The patient was advised regular follow-up after three and six weeks (Figures 3 and 4).

Discussion

NUP is an indication of severe immunosuppression. There is a strong correlation between NUP and CD4+ cell counts of less than 200 cells/mm³. The present case also showed a very high viral load and a CD4+ cell count of 75 cells/mm³. An interplay of host immune factors and viral load determine the severity and progression of NUP in HIV-positive patients [1]. Other contributing factors for NUP are tobacco smoking habit, candida infection in the sub-gingival region, poor oral hygiene, and undernourished status [6, 7].

The characteristic presentation of NUP is the rapid progression of necrosis of the soft tissue into alveolar bone, causing deep interdental crater formation. Commonly, these defects are situated in the premolar and molar regions. In the present case, alveolar bone destruction was prevalent, involving anterior and posterior segments of the upper and the lower arches [8].

Treatment approach for HIV-associated NUP lesions comprises of debridement of pseudo-membrane and necrotic tissues under systemic antibiotics, with strict follow-up protocols recommended at 3rd and 6th weeks, followed by 3-month intervals. This protocol eliminates the chance of possible recurrence of such lesions [9].

Our patient's speedy recovery and response to the treatment was attributed to the prompt initiation of highly active antiretroviral therapy that was guided by the typical intra-oral presentation, which was further confirmed by the CD4+ counts. The patient had significant reduction of the pain and rapid healing of the lesions due to thorough debridement and metronidazole therapy. She was kept on regular follow-up at three and six months, and there was no evidence of recurrence.

There are numerous oro-facial manifestations of HIV infections, and these features could often guide dental professionals in diagnosing unidentified systemic illness (HIV infection). This facilitates prompt and effective management and reduces the disease morbidity [10]. Ajila *et al.* reported a 35-years-old female who presented with post-herpetic osteonecrosis of the maxilla, which led to the diagnosis of HIV infection. Such cases emphasize the importance of identification of retro-positive status at the earliest, since there is an ever increasing number of HIV-positive patients in the population who are susceptible to various types of infections, which in turn can help us in instituting effective treatment without a delay [11].

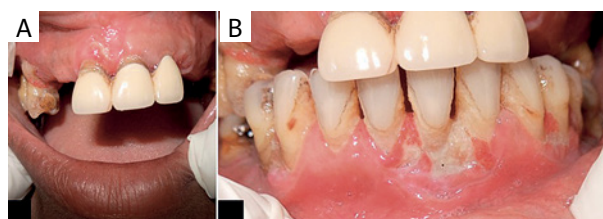


Figure 3. Two weeks post-op, following swabbing with hydrogen peroxide and supra gingival scaling

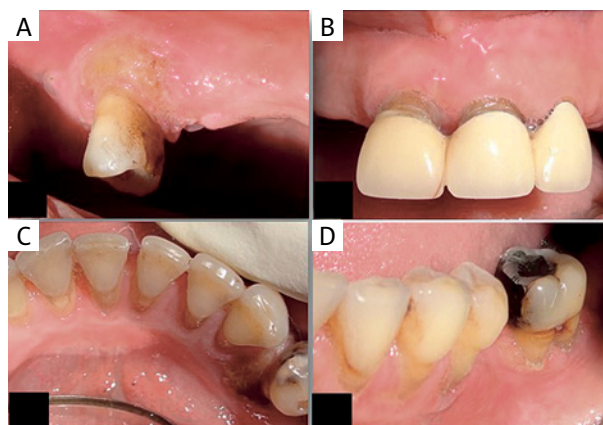


Figure 4. 6 weeks post-treatment, following swabbing with hydrogen peroxide and supragingival scaling

Conclusions

This case report highlights the significance of oral manifestations as the leading sign of the diagnosis of unidentified systemic illness. The bidirectional relationship that forms the oral-systemic link is of supreme importance for early and prompt diagnosis, thus facilitating timely management. Timely intervention will significantly reduce the burden of the disease, thus, improving morbidity and quality of life of HIV-positive patients.

Conflict of interest

The authors declare no conflict of interest.

References

- Glick M, Muzyka BC, Salkin LM, Lurie D. Necrotizing ulcerative periodontitis: a marker for immune deterioration and a predictor for the diagnosis of AIDS. *J Periodontol* 1994; 65: 393-397.
- Winkler JR, Murray PA. Periodontal disease a potential intraoral expression of AIDS may be rapidly progressive Periodontitis. *Calif Dent Assoc J* 1987; 15: 20-24.
- Karaaslan F, Dikilitaş A, Aydın EÖ. Comparison of periodontitis diagnoses according to 1999 and 2017 classifications: an original article. *Cumhuriyet Dent J* 2019; 22: 4.
- Malek R, Gharibi A, Khilil N, Kissa J. Necrotizing ulcerative gingivitis. *Contemp Clin Dent* 2017; 8: 496-500.

5. Hu J, Kent P, Lennon JM, Logan LK. Acute necrotising ulcerative gingivitis in an immunocompromised young adult. *BMJ Case Rep* 2015; 2015: Bcr2015211092.
6. Ratnam M, Nayyar AS, Reddy DS, Ruparani B, Chalapathi KV, Md SA. CD4 cell counts and oral manifestations in HIV infected and AIDS patients. *J Oral Maxillofac Pathol* 2018; 22: 282.
7. Lamster IB, Grbic JT, Mitchell-Lewis DA, Begg MD, Mitchell A. New concepts regarding the pathogenesis of periodontal disease in HIV infection. *Ann Periodontol* 1998; 3: 62-75.
8. Riley C, London JP, Burmeister JA. Periodontal health in 200 HIV-positive patients. *J Oral Pathol Med* 1992; 21: 124-127.
9. Dufty J, Gkraniats N, Donos N. Necrotising ulcerative gingivitis: a literature review. *Oral Health Prev Dent* 2017; 15: 321-327.
10. Pizzolato B, Abbott ME, Santos MA, et al. Oral manifestations in HIV patients. *J Interdiscipl Med Dent Sci* 2018; 6: 228.
11. Ajila V, Naidu GS, Gopagumar R. Post herpetic osteonecrosis of the maxilla. *Cumhuriyet Dent J* 2019; 22: 241-244.